

# Novel Administration Technique for Large-Particle Stabilized Hyaluronic Acid-Based Gel of Nonanimal Origin in Facial Tissue Augmentation

Woffles Wu · Ian Carlisle · Peter Huang ·  
Natalia Ribé · Rosalba Russo · Claudia Schaar ·  
Alexis Verpaele · Anders Strand

Received: 19 March 2009 / Accepted: 9 October 2009  
© Springer Science+Business Media, LLC and International Society of Aesthetic Plastic Surgery 2009

**Abstract** The use of large-particle stabilized hyaluronic acid-based gel of nonanimal origin (NASHA™) for facial aesthetic procedures is widespread and increasing. A panel of experts with extensive clinical experience with NASHA-based gel recently attended an advisory board meeting to develop guidelines for its use in volumetric tissue augmentation. Discussions included details of the blunt-cannula

injection technique currently recommended for administration of large-particle NASHA-based gel. With the aim of optimizing patient comfort and control over administration of NASHA-based gel, the panel members explored an alternative, sharp-needle technique. In this article we describe the new technique in detail, together with practical recommendations and precautions. The technique has several advantages over blunt-cannula injection: improved patient comfort, lack of need for a skin incision, increased precision regarding the implant position, and improved control of injection volume. However, the sharp-needle technique requires a high level of skill and a good knowledge of facial anatomy.

The consensus meeting was arranged by Q-Med and held on 12th February 2008 in Melbourne, Australia. All panel members received an honorarium for providing lectures and participating in this workshop.

W. Wu (✉)  
Woffles Wu Aesthetic Surgery & Laser Centre, 1 Orchard  
Boulevard, Suite 09-02, Camden Medical Centre, Singapore  
249615, Singapore  
e-mail: woffles@woffleswu.com

I. Carlisle  
Cabrini Hospital, Malvern, Australia

P. Huang  
Rebecca Cosmetic Center, Tao Yuan City, Taiwan

N. Ribé  
Institut Dra. Natalia Ribé, Barcelona, Spain

R. Russo  
Xsana Clinique, Modena, Italy

C. Schaar  
Fachärztin für Plastische und Ästhetische Chirurgie, Transmed  
Privatklinik GmbH, Wiesbaden, Germany

A. Verpaele  
Coupure Centre for Plastic Surgery, Ghent, Belgium

A. Strand  
University Hospital, Uppsala, Sweden

**Keywords** NASHA-based gel · Restylane · Hyaluronic acid · Facial tissue augmentation · Injection technique

Facial attractiveness is associated with regularity of facial features and pronounced convexity and concavity in the facial profile [1]. In recent years, the demand for nonsurgical facial rejuvenation procedures to improve perceived attractiveness and maintain a youthful appearance has increased considerably [2], with augmentation of facial features using injectable filler materials rapidly becoming one of the most frequently performed aesthetic procedures [3]. Statistics from the American Society for Aesthetic Plastic Surgery show that use of hyaluronic acid (HA) for nonsurgical cosmetic procedures in the United States (US) increased 59% between 2005 and 2006 [4], and a further 35% between 2006 and 2007 [5]. However, the rise in demand for cosmetic surgery procedures is not limited to older-age groups; in fact, the single greatest increase in demand for the use of HA in nonsurgical procedures in 2007 was among those aged 20–29 years (83%) [5].

In many ways, HA is an ideal substance to fill skin depressions; it is a naturally occurring polysaccharide, and an essential component of the dermal extracellular matrix that provides structure and volume to the skin. Furthermore, the chemical structure is consistent across species and tissues, minimizing the risk of immunological reactions and implant rejection [6, 7]. Endogenous HA is highly susceptible to enzymatic degradation and undergoes extremely rapid metabolic turnover *in vivo* (tissue half-life ranges from 12 h to a few days) [8]. Therefore, in order to support its use in cosmetic procedures, HA must be stabilized by crosslinking adjacent polymer chains to form an insoluble hydrogel matrix of high molecular weight. Stabilization of HA improves its resistance to degradation, thereby prolonging its tissue half-life [9]. Stabilized HA-based gel of nonanimal origin (NASHA<sup>TM</sup>-based gel; Q-Med AB, Uppsala, Sweden) was developed using patented technology and was first used for aesthetic purposes in clinical studies in the mid-1990s, when efficacy was demonstrated for correction of facial wrinkles and folds and in lip augmentation [10, 11]. A number of NASHA-based products have subsequently been developed and extensively studied in both the US and Europe; these studies have confirmed the safety and efficacy of NASHA-based gel in clinical practice [12–16]. It is now estimated that over 10 million aesthetic procedures have been performed worldwide using NASHA-based gels (Q-Med AB, data on file).

A NASHA-based product with larger particles than other NASHA-based (Restylane<sup>®</sup>) products has been developed. Large-particle NASHA-based gel (Restylane SubQ<sup>TM</sup>; Q-Med AB, Uppsala, Sweden) is intended for deep facial injection in patients requiring additional volume. It can be injected subcutaneously or supraperiosteally and is indicated for replacement of volume loss in adipose tissue and for the creation of more defined facial contours [3, 17–19]. It is also indicated for the treatment of facial lipoatrophy in patients with human immunodeficiency virus (HIV) [20, 21]. Large-particle NASHA-based gel is currently approved for use in over 30 countries, including the European Union, and is available to physicians trained by the manufacturer (Q-Med AB, Uppsala, Sweden).

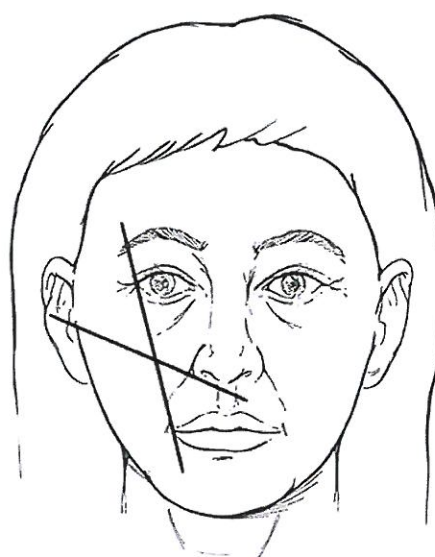
The initial injection technique recommended for administration of large-particle NASHA-based gel was via a blunt cannula, although recent experience with sharp-needle injection as an alternative approach has suggested that this may provide some advantages over blunt-cannula injection, without compromising safety. Re-evaluation of the injection procedure for large-particle NASHA-based gel led to an extended CE approval in 2007, which included the use of sharp needles. With the widespread and growing use of large-particle NASHA-based gel for facial tissue augmentation, a panel of experts with extensive

clinical experience of NASHA-based gels convened to develop consensus guidelines for its use. Discussions included a comparison of the original blunt-cannula approach with the new sharp-needle method.

### Currently Recommended Blunt-Cannula Technique

The initial recommendations for using large-particle NASHA-based gel comprised blunt-cannula administration only. It was recommended that an incision first be made in the skin with either a No. 11 scalpel blade or an 18G sharp needle, before injection of a blunt 16–19G cannula (typically 18G) at a distal location. It was suggested that the overlying tissue should be tented with the cannula tip to ensure the correct injection depth, and the large-particle NASHA-based gel injected using a retrograde technique with the cannula tip facing downward. The group advised that the Hinderer model typically should be used prior to injection of large-particle NASHA-based gel to determine the position of the cannula tip, thereby ensuring correct placement of the gel (Fig. 1) [22]. The use of anesthesia was also recommended prior to injection. The group discussed whether local nerve blocks or topical anesthetics may be preferable, but a consensus was not achieved; some panel members prefer to use nerve blocks, whereas others prefer to use only topical anesthetics.

Blunt-cannula administration of large-particle NASHA-based gel may be performed via either the transoral route [23] or the transdermal route [24]. The transdermal route requires an incision to be made in the skin, and the cannula



**Fig. 1** Hinderer's lines. Two intersecting lines: one from the ala to the tragus and one from the lateral canthus. Restylane SubQ should be placed in the upper outer quadrant



to be inserted at an angle horizontal to the skin surface; use of the oral route obviates the need for an incision in the skin. Although there is a theoretical increase in the risk of soft-tissue infection associated with injection via the oral route, there are no published reports of increased rates of infection following the administration of large-particle NASHA-based gel via the transoral route, and the panel members have not experienced any instances of infection. The consensus was to recommend precautionary use of a cyclohexidine-based mouthwash 24 h before and 24 h after injection, as per the procedure used for insertion of dental implants. The group also agreed that the prophylactic use of antibiotics is unnecessary when injecting large-particle NASHA-based gel via the oral route as salivary proteins exert an antibacterial effect [25].

Despite the widespread use of the blunt-cannula technique for injecting large-particle NASHA-based gel, it has several inherent disadvantages. First, the panel members consider the blunt-cannula technique to be a relatively “aggressive” procedure for conscious patients, and one that some patients find somewhat distressing. According to clinical experience, a proportion of patients report awareness of the cannula being inserted despite being anaesthetized. Furthermore, the design of the cannula (with the opening facing downward) introduces the potential for too much product to be administered into the target tissue. In

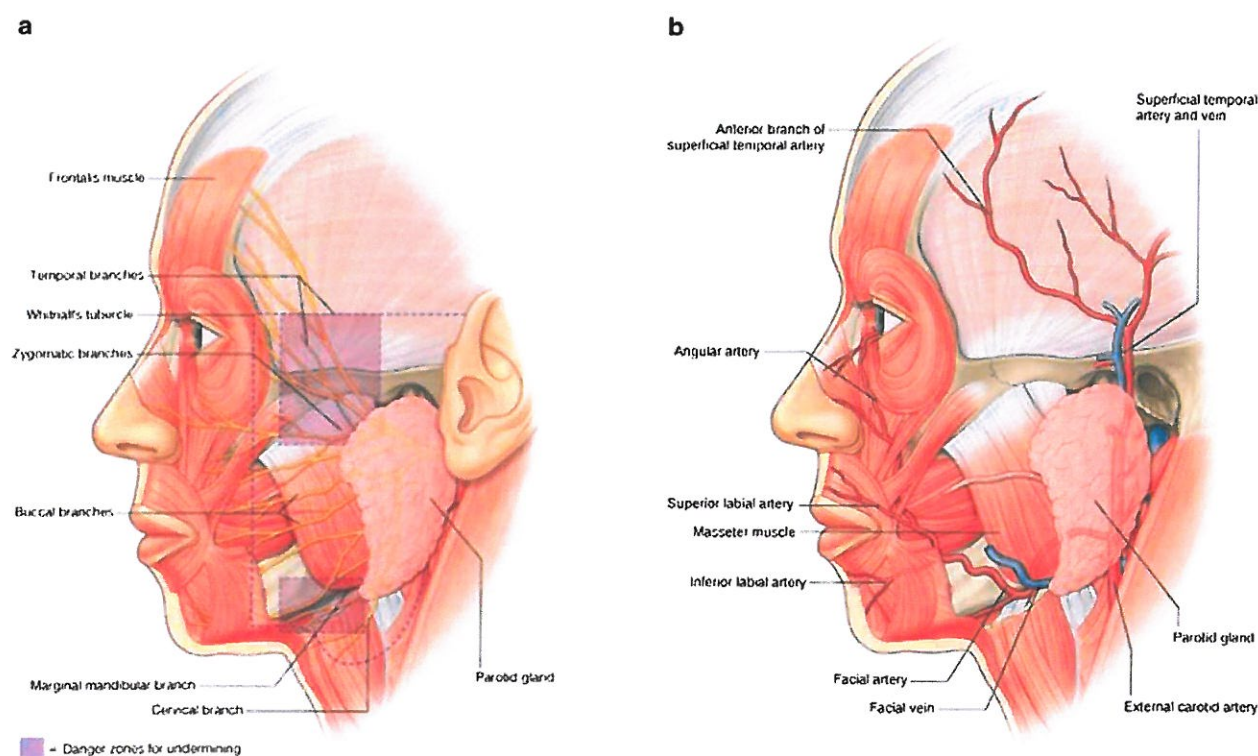
such cases, aspiration or injection of small amounts of hyaluronidase can remove excess NASHA-based gel [26].

## New Sharp-Needle Technique

### Rationale and Facial Anatomy

An alternative technique has been developed recently for injecting large-particle NASHA-based gel to achieve facial tissue augmentation—the sharp-needle technique. One reason for the development of a new injection technique was to increase the level of patient comfort during the procedure; use of a sharp needle for injection should reduce the ability of the patient to “feel” the needle. The second reason was to avoid the requirement for an incision in the skin; a sharp needle can be inserted directly through the skin. The transdermal route can therefore be adopted routinely when using the sharp-needle technique.

Physicians considering use of the sharp-needle technique require a good knowledge of facial anatomy (Fig. 2). Detailed understanding of the structures underneath the cutaneous surface is essential to avoid damaging vital structures such as the facial nerve and its branches, other sensory and motor nerves, the parotid duct, and blood vessels. In some areas the facial nerve is scarcely protected,



**Fig. 2** Facial anatomy. **a** Branches of facial nerve and danger zones for undermining. **b** Arterial supply of the face (reproduced from [31])

**Table 1** Nerve structures potentially at risk during sharp-needle injection of large-particle NASHA-based gel

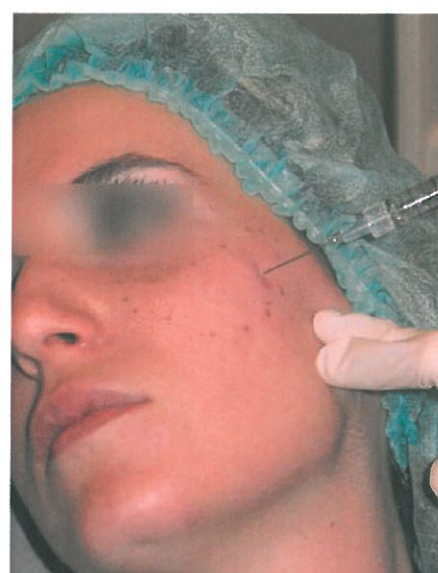Structure	Function	Likely effect of a lesion
Temporal branch of the facial nerve	Motor nerve for the lateral and distal regions of the frontal muscle	Partial incapacity of muscle contraction
Marginal mandibular branch of the facial nerve	Motor nerve for the depressor anguli oris and the depressor labii inferioris muscles	Incapacity of muscle contraction on the lower portion of the lip and a deviation of the contralabial mouth angle
Supraorbitalis and supratrochlearis nerves	Sensory nerves of the frontal region	Sensitivity alterations of the frontal region
Infraorbitalis nerve	Sensory nerve, responsible for sensitivity of the lower eyelid, nasal ala, and upper lip	Sensitivity alterations
Mentalis nerve	Sensory nerve, responsible for the sensitivity of the lower lip and the genial region	Sensitivity alterations

being covered merely by layers of cutis, subcutis, and the superficial musculoaponeurotic system (SMAS). When administering large-particle NASHA-based gel, it is important to proceed carefully around the so-called “facial risk zones” to avoid causing temporary or permanent damage to a facial nerve.

Potentially vulnerable nerve structures are summarized in Table 1. It is also necessary to avoid damaging major blood vessels. The facial artery, a branch of the external carotid artery, is commonly thought to terminate as the “angular artery.” This supplies the superior and inferior labial arteries and the nasal artery and runs parallel to the facial vein. However, in many cases, the facial artery actually terminates as a nasal and columellar artery, which both curve around the alar of the nose and unite as a rich plexus over the alar lobule and the tip of the nose [27]. The dorsal nasal artery, which is an external continuation of the ophthalmic artery, runs down over the dorsum of the nose and also enters this vascular plexus. Injection of NASHA-based gel into the facial artery is unlikely to cause thrombosis because the plexus over the nose is supplied by two different arterial systems, but bruising can occur so care is required during the injection. The cheek veins create a rich network, which essentially consists of three main branches. The first branch is found in a medial position with reference to the facial vein. It is located behind and to one side of the facial artery, whose route it shares before reaching the neck and joining the internal jugular vein. The second branch is located to one side of the superficial temporal vein. Finally, the third branch is located deep behind the pterygoid complex.

### Methodology

The panel members have recently piloted the use of a sharp needle (21G or 23G) for injection of large-particle NASHA-based gel to assess its use in clinical practice. The consensus of the physicians was that the sharp needle

**Fig. 3** Injection technique using the sharp needle (© N. Ribé)

should enter the skin at an angle of 70°–90° to the surface (i.e., perpendicular as opposed to parallel technique: vertically insert the needle down to the desired tissue plane or to the bone/periosteum; Fig. 3) to minimize the risk of injury. The gel should then be injected slowly, in a retrograde manner with a microbolus technique. To determine the correct area for injection of large-particle NASHA-based gel, the panel again considered the Hinderer model to be useful. The tumescence test was also considered to be a useful tool prior to injection (via blunt cannula or sharp needle), as it would allow the patient to visualize the effect of augmentation prior to treatment. The midface is one of the most powerful areas to change facial appearance; therefore, care must be taken to ensure that the patient will not feel that he/she looks “strange” following augmentation. Large-particle NASHA-based gel should be injected deep below the orbicularis oculi muscle within the lower

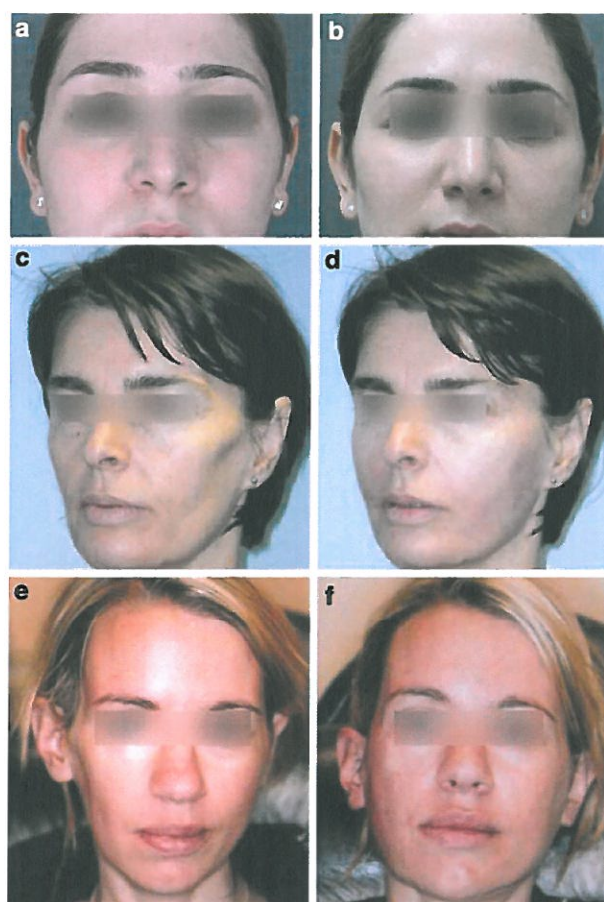


cheek. The correct placement of the product is anterior to the periosteum (unless the specific anatomy of the area being injected prevents this). The panel advised that large-particle NASHA-based gel should not be injected above the orbicularis oculi muscle as this can cause lumpiness. Injection in the vicinity of the buccal fat pad is also not advisable because insufficient outward projection of the tissue in this area usually cannot be achieved. Similar to the blunt-cannula technique, overcorrection with large-particle NASHA-based gel may be resolved by aspiration or by administration of small amounts of hyaluronidase.

Because the newly developed technique involves the use of a sharp needle, the group advised that precautions must be taken by the physician to minimize the risk of injury to the patient, in particular, the potential for intravascular injection. Sharp-needle injection of filler material significantly increases the risk of vascular embolism; high-pressure injection of material directly into a blood vessel has been reported to result in necrosis, blindness, and stroke [28–30]. It is therefore considered important to administer a local anesthetic containing epinephrine before sharp-needle injection of large-particle NASHA-based gel to induce vasoconstriction and minimize the risk of intravascular injection. The panel members also highly recommended precautionary aspiration prior to sharp-needle injection. Additional methods for minimizing the risk of intravascular injection include the application of an ice mask to the skin prior to injection and the use of a microbolus technique (see Table 2).

### Experience

Collectively, the panel members have treated approximately 1650 patients with large-particle NASHA-based gel for augmentation of facial tissue, generally in the cheeks and the chin (Fig. 4). Other areas less frequently treated include the deep nasolabial folds, loss of supporting structures close to the oral area, and the mandibular arch. In clinical practice, the sharp-needle technique allows greater precision in delivering the product close to the target site and affords the physician greater control than the blunt-cannula method. The potential for administering too much product is also reduced. In general, it is preferable to administer too little of the



**Fig. 4** Pre- and post-treatment photographs of three female patients who underwent soft tissue augmentation using the sharp-needle technique. The post-treatment photographs demonstrate the correction following administration of Restylane SubQ. **a** Pretreatment photo. **b** Four weeks postinjection of 4 ml of Restylane SubQ into the cheeks (© C. Schaar). **c** Pretreatment photo of 45-year-old patient. **d** Immediately postinjection of 2 ml of Restylane SubQ into the infraorbital grooves and 10 ml into the cheeks, malar, and midface regions (© W. Wu). **e** Pretreatment photo. **f** Twelve months postinjection of 8 ml of Restylane SubQ into the temporal, submalar, masseter, and lateral cheek (© I. Carlisle)

product and have the patient return for a touch-up treatment rather than administer too much.

Importantly, patient comfort is generally improved with sharp-needle injection of large-particle NASHA-based gel

**Table 2** Techniques to reduce the risk of intravascular injection with the sharp-needle technique

Technique	Physiological effect
Local administration of epinephrine	Pharmacological vasoconstriction for 30–60 min. Recommended to reduce bruising and bleeding
Aspiration prior to injection	If any blood returns into the syringe, then a blood vessel has been cannulated; it would then be mandatory to reposition prior to injection
Microbolus injection	Reduces the size of the bolus and therefore reduces the severity of the potential adverse event
Local application of ice packs prior to and following injection	Shunts blood away from site of injection for several minutes after discontinuation of ice pack. Also recommended to reduce bruising and bleeding



compared with administration by blunt cannula. There was unanimous agreement that overall patient comfort must be of paramount importance. A related consideration is whether the sharp-needle technique may affect the risk of bruising compared to the blunt-cannula approach. None of the panel members found evidence of increased bruising when using the new sharp-needle technique. The general consensus was that the likelihood of bruising depends more on the patient than the injection technique; some patients are more likely to experience bruising than others.

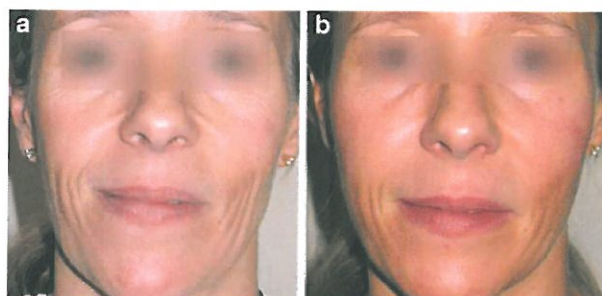A further discussion point was whether the properties of large-particle NASHA-based gel may be affected by passing it through a sharp needle. The choice of technique does not appear to affect the longevity of the product; a number of panel members have injected patients with NASHA-based gel via both the blunt cannula and the sharp needle in separate visits and found no difference in the duration of the facial augmentation. According to the manufacturer's recommendations, a 21G needle should be used with large-particle NASHA-based gel. However, it is the experience of the panel members that a 23G needle may also be suitable.

#### Case Studies

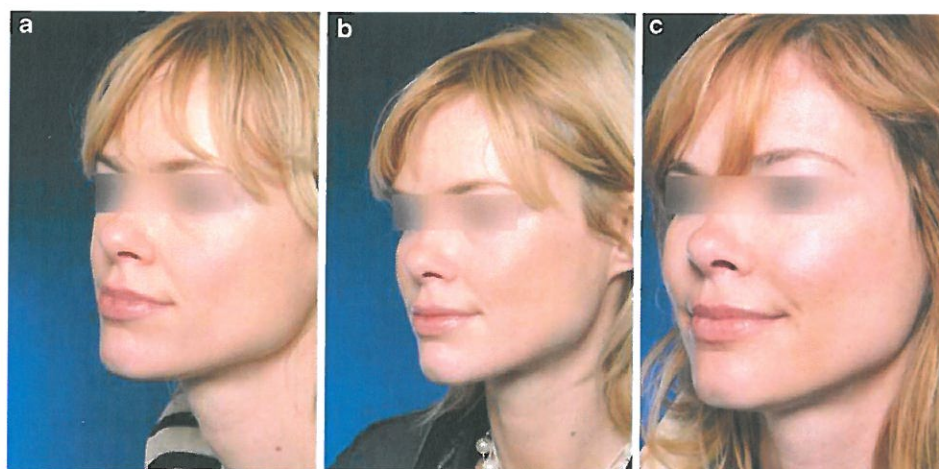
Figure 5a shows a 34-year-old woman who requested correction of facial deflation in December 2004, with emphasis on malar volume. The patient was treated with 1 ml of large-particle NASHA-based gel injected over the zygomatic bone via the transoral route using an 18G blunt cannula. The patient reported slight postoperative discomfort for 48 h after treatment, but there were no complications associated with the procedure and the patient was satisfied with the cosmetic result (Fig. 5b). The patient underwent

additional injections of NASHA-based gel via the transoral route in August 2005, June 2006, and May 2007, again with satisfactory aesthetic results. When the patient returned for her latest treatment in August 2008, she was treated with 1 ml of NASHA-based gel administered using a 21G sharp needle via the transdermal route (Fig. 5c). The patient described significantly improved comfort with the sharp-needle technique compared to the blunt-cannula approach, mainly because of less "jerky" movements. Significantly less post-treatment discomfort was also reported. The aesthetic improvement was found to be similar with both administration techniques.

A second case study is illustrated in Fig. 6. A 35-year-old woman presented with loss of soft tissue in both malar and cheek areas. A total of 10 ml of Restylane SubQ was injected into both malar and cheek areas using a 23G, 30-mm sharp needle. This volume was administered over two treatment sessions, 2 weeks apart, with 5 ml injected



**Fig. 6** Frontal view of 35-year-old patient (a) before and (b) 1 month after treatment with 10 ml of Restylane SubQ. The gel was injected into both malar and cheek areas using a 23G, 30-mm sharp needle (two treatment sessions 2 weeks apart, 5 ml per session; © N. Ribé)



**Fig. 5** a Pretreatment photograph of a 34-year-old patient who requested correction of facial deflation, with emphasis on malar volume. b Post-treatment view 3 weeks following blunt-cannula administration of 1 ml of Restylane SubQ over the zygomatic bone

via the transoral route. c Post-treatment view 3 weeks following sharp-needle administration of 1 ml of Restylane SubQ via the transdermal route (© A. Verpaele)



per session. The material was injected into the space between the supraperiosteum and the muscle using a linear retrograde and fan technique. The final result was a natural-looking enhancement of the malar and cheek areas.

## Discussion and Conclusion

Although the blunt-cannula approach remains a valid and recommended method for administration of large-particle NASHA-based gel, panel members indicate that there is a trend toward increased use of the sharp-needle technique. This is attributable to improved patient comfort, lack of the need for a skin incision, increased precision regarding implant position, and improved control of injection volume with the sharp-needle technique. It must be acknowledged that the blunt-cannula approach can now be pursued using new, thinner cannulae. Compared with the original blunt-cannula approach, the new cannulae minimize bruising, discomfort, and the risk of vascular or nerve injury. However, important disadvantages relative to the sharp-needle technique remain: skin puncture using a cannula is still required and high injection resistance may be encountered.

The availability of two different injection techniques for facial indications should be pointed out to potential future users of large-particle NASHA-based gel. Training on both techniques should be provided, including details of their relative advantages and disadvantages. Clinicians can then select their preferred administration method depending on their level of skill/expertise with the product. A study comparing sharp-needle with blunt-cannula injection would be valuable in this context, probably of split-face design to facilitate clinical comparison. Use of the sharp-needle technique requires a high level of skill, and a good knowledge of facial anatomy is imperative to avoid trauma to the infraorbital nerve. Both techniques can be used safely if performed correctly. As with all cosmetic procedures, patient safety and comfort should be the primary considerations when selecting the appropriate administration technique. Other aspects of injection should also be taken into consideration, such as the type of anesthesia required.

In conclusion, for physicians with appropriate knowledge and experience, the sharp-needle technique appears to provide several advantages over the blunt-cannula approach without compromising safety.

## References

1. Sergl HG, Zentner A, Krause G (1998) An experimental study of the esthetic effect of facial profiles. *J Orolfac Orthop* 59:116–126
2. Rohrich RJ, Rios JL, Fagien S (2003) Role of new fillers in facial rejuvenation: a cautious outlook. *Plast Reconstr Surg* 112:1899–1902
3. Verpaele A, Strand A (2006) Restylane SubQ, a non-animal stabilized hyaluronic acid gel for soft tissue augmentation of the mid- and lower face. *Aesthet Surg J* 26:S10–S17
4. American Society for Aesthetic Plastic Surgery. Cosmetic surgery national data bank statistics 2006. Available at <http://www.plasticsurgery.org/media/statistics>. Accessed October 2008
5. American Society for Aesthetic Plastic Surgery. Cosmetic surgery national data bank statistics 2007. Available at <http://www.plasticsurgery.org/media/statistics>. Accessed October 2008
6. Larsen NE, Pollak CT, Reiner K, Leshchiner E, Balazs EA (1993) Hylan gel biomaterial: dermal and immunologic compatibility. *J Biomed Mater Res* 27:1129–1134
7. Matarasso SL, Carruthers JD, Jewell ML (2006) Consensus recommendations for soft-tissue augmentation with nonanimal stabilized hyaluronic acid (Restylane). *Plast Reconstr Surg* 117:3S–34S; discussion 35S–43S
8. Tammi R, Saamanen AM, Maibach HI, Tammi M (1991) Degradation of newly synthesized high molecular mass hyaluronan in the epidermal and dermal compartments of human skin in organ culture. *J Invest Dermatol* 97:126–130
9. Band PA (1998) Hyaluronan derivatives: chemistry and clinical applications. In: Laurent TC (ed) *The chemistry, biology and medical applications of hyaluronan and its derivatives*. Portland Press, London, pp 33–42
10. Duranti F, Salti G, Bovani B, Calandra M, Rosati ML (1998) Injectable hyaluronic acid gel for soft tissue augmentation. A clinical and histological study. *Dermatol Surg* 24:1317–1325
11. Olenius M (1998) The first clinical study using a new biodegradable implant for the treatment of lips, wrinkles, and folds. *Aesthetic Plast Surg* 22:97–101
12. Andre P (2004) Evaluation of the safety of a non-animal stabilized hyaluronic acid (NASHA-Q-Medical, Sweden) in European countries: a retrospective study from 1997 to 2001. *J Eur Acad Dermatol Venereol* 18:422–425
13. Carruthers A, Carey W, De Lorenzi C, Remington K, Schachter D, Sapra S (2005) Randomized, double-blind comparison of the efficacy of two hyaluronic acid derivatives, Restylane Perlane and Hylaform, in the treatment of nasolabial folds. *Dermatol Surg* 31:1591–1598; discussion 1598
14. Friedman PM, Mafong EA, Kauvar AN, Geronemus RG (2002) Safety data of injectable nonanimal stabilized hyaluronic acid gel for soft tissue augmentation. *Dermatol Surg* 28:491–494
15. Lindqvist C, Tveten S, Bondevik BE, Fagrell D (2005) A randomized, evaluator-blind, multicenter comparison of the efficacy and tolerability of Perlane versus Zyplast in the correction of nasolabial folds. *Plast Reconstr Surg* 115:282–289
16. Narins RS, Brandt FS, Lorenc ZP, Maas CS, Monheit GD, Smith SR, McIntyre S (2007) A randomized, multicenter study of the safety and efficacy of Dermicol-P35 and non-animal-stabilized hyaluronic acid gel for the correction of nasolabial folds. *Dermatol Surg* 33(Suppl 2):S213–S221; discussion S221
17. De Lorenzi C, Weinberg M, Solish N, Swift A (2009) The long-term efficacy and safety of a subcutaneously injected large-particle stabilized hyaluronic acid-based gel of nonanimal origin in aesthetic facial contouring. *Dermatol Surg* 35(Suppl 1):313–321
18. DeLorenzi C, Weinberg M, Solish N, Swift A (2006) Multicenter study of the efficacy and safety of subcutaneous non-animal-stabilized hyaluronic acid in aesthetic facial contouring: interim report. *Dermatol Surg* 32:205–211
19. Lowe NJ, Grover R (2006) Injectable hyaluronic acid implant for malar and mental enhancement. *Dermatol Surg* 32:881–885; discussion 885

20. Bugge H, Negaard A, Skeie L, Bergersen B (2007) Hyaluronic acid treatment of facial fat atrophy in HIV-positive patients. *HIV Med* 8:475–482
21. Strand A, Wolters M (2006) HIV-related lipodystrophy and facial lipoatrophy: the role of Restylane SubQ in reversing facial wasting. *Aesthet Surg J* 26:S35–S40
22. Constantinides MS, Galli SK, Miller PJ, Adamson PA (2000) Malar, submalar, and midfacial implants. *Facial Plast Surg* 16: 35–44
23. Sito G (2006) Transoral injection of Restylane SubQ for aesthetic contouring of the cheeks. *Aesthet Surg J* 26:S22–S27
24. Belmontesi M, Grover R, Verpaele A (2006) Transdermal injection of Restylane SubQ for aesthetic contouring of the cheeks, chin and mandible. *Aesthet Surg J* 26:S28–S34
25. Tenovuo J, Lumikari M, Soukka T (1991) Salivary lysozyme, lactoferrin and peroxidases: antibacterial effects on cariogenic bacteria and clinical applications in preventive dentistry. *Proc Finn Dent Soc* 87:197–208
26. Vartanian AJ, Frankel AS, Rubin MG (2005) Injected hyaluronidase reduces Restylane-mediated cutaneous augmentation. *Arch Facial Plast Surg* 7:231–237
27. Wu W (1992) The Oriental nose: an anatomical basis for surgery. *Ann Acad Med Singapore* 21:176–189
28. Castillo GD (1989) Management of blindness in the practice of cosmetic surgery. *Otolaryngol Head Neck Surg* 100:559–562
29. Feinendegen DL, Baumgartner RW, Vuadens P, Schroth G, Mattle HP, Regli F, Tschopp H (1998) Autologous fat injection for soft tissue augmentation in the face: a safe procedure? *Aesthetic Plast Surg* 22:163–167
30. Silva MT, Curi AL (2004) Blindness and total ophthalmoplegia after aesthetic polymethylmethacrylate injection: case report. *Arq Neuropsiquiatr* 62:873–874
31. Robinson JK, Sengelmann RD, Hanke CW, Siegel DM (2005) *Surgery of the skin*. Elsevier Mosby, New York